

Effectiveness of the SpineCor Brace Based on the New Standardized Criteria Proposed by the Scoliosis Research Society for Adolescent Idiopathic Scoliosis

Christine Coillard, MD,* Valerie Vachon, MSc,† Alin B. Circo, MSc,* Marie Beauséjour, MScA,* and Charles H. Rivard, MD, FRCS(c), FAAOS, FACS*

Abstract: The purpose of this prospective observational study was to evaluate the effectiveness of the Dynamic SpineCor brace for adolescent idiopathic scoliosis in accordance with the standardized criteria proposed by the Scoliosis Research Society Committee on Bracing and Nonoperative Management. They proposed these guidelines to make the comparison among studies more valid and reliable. From 1993 to 2006, 493 patients were treated using the SpineCor brace. Two hundred forty-nine patients met the criteria for inclusion, and 79 patients were still actively being treated. Overall, 170 patients have a definitive outcome. All girls were premenarchal or less than 1 year postmenarchal. Assessment of brace effectiveness included (1) percentage of patients who have 5 degrees or less curve progression, and percentage of patients who have 6 degrees or more progression; (2) percentage of patients who have been recommended/undergone surgery before skeletal maturity; (3) percentage of patients with curves exceeding 45 degrees at maturity (end of treatment); and (4) Two-year follow-up beyond maturity to determine the percentage of patients who subsequently underwent surgery. Successful treatment (correction, >5 degrees, or stabilization, ± 5 degrees) was achieved in 101 (59.4%) of the 170 patients from the time of the fitting of the SpineCor brace to the point in which it was discontinued. Thirty-nine immature patients (22.9%) required surgical fusion while receiving treatment. Two (1.2%) of 170 patients had curves exceeding 45 degrees at maturity. One mature patient (2.1%) required surgery within 2 years of follow-up beyond skeletal maturity. The conclusion drawn from these findings is that the SpineCor brace is effective for the treatment of adolescent idiopathic scoliosis. Moreover, positive outcomes are maintained after 2 years because 45 (95.7%) of 47 patients stabilized or corrected their end of bracing Cobb angle up to 2 years after bracing. Therapeutic study—investigating the results of treatment: level II.

Key Words: adolescent idiopathic scoliosis, conservative treatment effectiveness, SpineCor brace, standardized criteria

(*J Pediatr Orthop* 2007;27:375–379)

From the *Research Center, Sainte-Justine Hospital, Montreal, Quebec, Canada, and †SpineCor Corporation Limited.

Study conducted at the Research Center, Sainte-Justine Hospital and University of Montreal, Canada.

Study was funded by the Research Center, Sainte-Justine Hospital and the Spine Corporation.

Reprints: Charles H. Rivard, MD, FRCS(c), FAAOS, FACS, Research Center, Sainte-Justine Hospital, 3175 Côte Ste-Catherine, Montreal, Quebec, Canada H3T 1C5. E-mail: chrivard@gmail.com.

Copyright © 2007 by Lippincott Williams & Wilkins

Many conservative treatments are available for adolescents with idiopathic scoliosis (AIS). Although there are numerous studies in literature that have tried to summarize the results of treatment,^{1–7} the evidence for their accepted use is still unclear.⁸ In addition, the lack of consistency of both the inclusion criteria and the definitions of brace effectiveness⁹ makes many clinicians skeptical about the efficacy of conservative treatments.^{10,11}

The Scoliosis Research Society (SRS) thought it was necessary to establish parameters for all future AIS bracing studies⁹ to be able to make comparison among studies more valid and reliable. Such guidelines will allow the promotion of the effectiveness of different braces using different approaches, for instance the 3-point pressure principle used by rigid braces and the Corrective Movement used by the Dynamic SpineCor brace (Fig. 1).

The effectiveness of the SpineCor brace has been shown for milder and moderate curves.¹ The purpose of the present review is to evaluate the effectiveness of the SpineCor brace for AIS in accordance with the new standardized criteria proposed by the SRS Committee on Bracing and Nonoperative Management.⁹

METHODS

The Studied Population

This prospective observational study was conducted on a group of 493 patients (92.7% girls) having idiopathic scoliosis treated with the SpineCor brace.

Radiographic Analysis

The initial pretherapeutic radiograph used a digital technique where the irradiation is half as much as that of a standard radiograph.¹² The initial evaluation included a posteroanterior and a lateral radiograph without brace within a maximum of 1 month before brace fitting. Control radiographs (erect posteroanterior position) with the SpineCor brace (and shoe lift when prescribed) were obtained on the day of the fitting, at 4 to 6 weeks, and then every 5 months until weaning. Lateral radiographs were obtained once a year. At the end of the treatment, the use of controls was continued at 6 months, 1 year, and once every year. These evaluations were performed without brace.

The inclusion criteria were as follows:

- idiopathic scoliosis diagnosis and radiological confirmation of absence of significant pathological malformation of the spine;

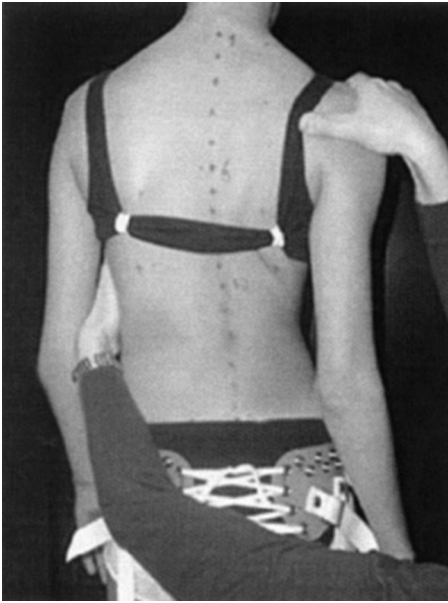


FIGURE 1. Corrective Movement for the right thoracic type 1 curve: counterclockwise rotation of the thorax and clockwise rotation of the shoulders in the horizontal plane.

- age older than 10 years and younger than 15 years when brace is prescribed;
- Risser 0, 1, or 2;
- if female, either premenarchal or less than 1 year postmenarchal;
- initial Cobb angle of 25 degrees or greater;
- initial Cobb angle of 40 degrees or lesser; and
- no previous treatment for scoliosis.

The exclusion criteria were as follows:

- presence of a congenital malformation of the spine, spina bifida aperta, or spondylolisthesis;
- neuromuscular scoliosis; and
- postural scoliosis.

Skeletal maturity is considered achieved when Risser 4 or more is reached and, in girls, when the patient is 2 years postmenarchal. The US grading system¹³ for Risser sign was used in this study. Taking into account the criteria mentioned, we needed to exclude some patients from the actual study. Of 493 patients who accepted the treatment using the SpineCor brace between 1993 and 2006, 59 patients were younger than 10 years at the initial visit, 61 patients had a Risser 3 to 5 or were more than 1 year postmenarchal, 112 had an initial Cobb angle less than 25 degrees, and 12 patients had a curvature greater than 40 degrees. From the remaining 249 patients who respected those inclusion criteria, 79 patients were still actively being treated at the time of the analysis, for a total of 170 patients with an outcome. From this cohort of patients, 47 patients had 2 years of follow-up after weaning of the brace.

Description of the Bracing System and Treatment Protocol

The Dynamic SpineCor brace, developed in 1992–1993, uses a specific Corrective Movement dependent on the type of the curve. Curve classification was based on the classification presented by Ponseti and Friedman.¹⁴ The curve-specific Corrective Movement is performed, and the brace is applied according to definitions contained in the SpineCor Assistant software. To be effective and to obtain a neuromuscular integration, the brace must maintain and amplify the corrective movement over time. The brace must be worn 20 hours a day for a minimum of 18 months to create a neuromuscular integration of the Corrective Movement through active biofeedback. Generally, the brace is stopped at skeletal maturity (at least Risser 4) (Fig. 2).

Improvement of more than 5 degrees or stabilization of ±5 degrees of the scoliosis curvature was defined as a positive outcome. An aggravation of the spinal curvature of more than 5 degrees, progression exceeding 45 degrees, withdrawal, and surgery were defined as negative outcomes. The data collected were analyzed in 4 outcomes, as suggested by the SRS Committee on Bracing and Nonoperative Management.⁹ To strengthen the ability to compare and combine results

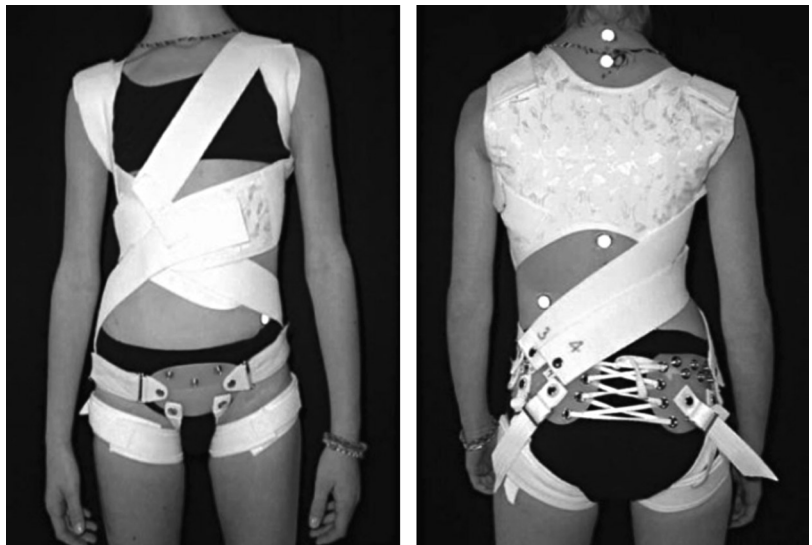

FIGURE 2. Front and back views of the SpineCor brace fitted for the right thoracic type 1 curve: the brace keeps and stimulates the specific corrective movement for the right thoracic curve.

across studies, we stratified our results according to curve type, curve magnitude grouping, and skeletal maturity. Descriptive statistics were used to analyze the population.

RESULTS

One hundred seventy patients (158 girls and 12 boys) treated using the SpineCor brace respected the inclusion criteria and were not actively being treated. All girls were premenarchal or less than 1 year postmenarchal. Thirty-nine immature patients required surgery during brace treatment, 12 patients withdrew from the SpineCor treatment and refused any other conservative treatment, and 14 patients were weaned before reaching skeletal maturity because they had an authorized end of treatment and a Cobb angle inferior representing a stable corrective result. Forty-seven patients had 2 years of postbracing follow-up.

Assessment of brace effectiveness includes all of the following:

1) Percentage of patients who have 5 degrees or less curve progression and the percentage of patients who have 6 degrees or more progression.

One hundred one (59.4%; 87 + 14) of 170 patients corrected or stabilized their initial Cobb angle, and 18 patients (10.6%) had 6 degrees or more progression of their initial Cobb angle (without surgery) (Table 1).

Forty-seven patients with a successful outcome at the weaning point reached the 2 years of follow-up.

With postbrace treatment follow-up observation (Table 2), the treatment success rate at 2 years was 95.7% (n = 47), comparing the end of bracing Cobb angle with the one at 2 years after bracing. Forty of 47 patients stabilized their Cobb angle, and 5 patients still improved from the time the brace was discontinued up to 2 years of follow-up.

2) Percentage of patient who have had surgery recommendation/undergone before skeletal maturity.

TABLE 2. Outcome for the 47 Patients Treated Using the SpineCor Brace, Comparing the Cobb Angle at the Weaning Point With the One at 2 Years of Follow-up After Bracing

	SpineCor Dynamic Corrective Bracing (n = 47)			
	≤5 Degrees	>5 Degrees	>45 Degrees*	Surgery†
No. patients	45	2	4	1
Type of curve				
Thoracic	18	2	3	1
Thoracolumbar	12	0	0	0
Double	12	0	1	0
Lumbar	3	0	0	0
Initial Cobb angle				
[25–29 degrees]	21	0	0	0
[30–40 degrees]	24	2	4	1
Initial Risser sign				
0	25	2	4	1
1	9	0	0	0
2	11	0	0	0

*Four patients had a scoliosis beyond 45 degrees angle at maturity 2 years after bracing. Only 2 of them had a progression of their Cobb angle after the weaning point; the 2 other patients had a stabilization of their scoliosis. Their initial Cobb angles were 40 degrees, 36 degrees, 40 degrees, and 39 degrees, and their Cobb angle at the end of bracing were 44 degrees, 42 degrees, 51 degrees, and 51 degrees, respectively. Their Cobb angles at 2 years of follow-up after bracing visit were 47 degrees, 48 degrees, 55 degrees, and 61 degrees.

†Regarding this particular subgroup of patients, surgery was required for the patient who had a Cobb angle of 39 degrees at the initial visit, 51 degrees at the end of bracing, and 61 degrees at the last visit after bracing. Surgical treatment was not an option for the 3 other patients with a Cobb angle beyond 45 degrees.

Thirty-nine immature patients (22.9%) from a total of 170 required surgical fusion while receiving treatment (Table 1). The average curve magnitude at bracing in this particular group was 34 ± 5.1 degrees (range, 25–40 degrees). The general indication for fusion in all patients was progression of primary curve at more than 60 degrees

TABLE 1. Outcome for the 170 Patients Treated Using the SpineCor Brace, Comparing the Initial Cobb Angle With the One at the Weaning Point

	SpineCor Dynamic Corrective Bracing (n = 170)				Withdraw	Surgery†	Total
	≤5 Degrees	>5 Degrees	(>45 Degrees)	Patient Weaned Before Skeletal Maturity*			
No. patients	87	18	(2)	14	12	39	170
Type of curve							
Thoracic	37	10	(2)	5	3	19	74
Thoracolumbar	29	1	(0)	5	5	9	49
Double	13	6	(0)	2	3	11	35
Lumbar	8	1	(0)	2	1	0	12
Initial Cobb angle							
[25–29 degrees]	37	10	(0)	10	4	6	67
[30–40 degrees]	50	8	(2)	4	8	33	103
Initial Risser sign							
0	39	17	(2)	13	7	36	112
1	23	0	(0)	1	1	2	27
2	25	1	(0)	0	4	1	31

*The 14 patients received an authorized end of treatment because of a stable corrective result.

†Of the 39 patients requiring corrective surgery, 36 had a Risser sign 0 at the beginning of treatment and 33 were in the group with Cobb angle of 30 to 40 degrees.

in thoracic region and 45 degrees in thoracolumbar and lumbar regions.

3) Percentage of patients with curves exceeding 45 degrees at maturity.

In addition to patients referred for surgery before maturity, 2 of 170 patients progressed beyond 45-degree curve at maturity (end of bracing Cobb angle) (Table 1).

4) Two-year follow-up beyond maturity to determine the percentage of patients who subsequently undergo surgery.

Four (8.5%) of 47 patients had curves exceeding 45 degrees at 2 years of follow-up (Table 2). However, only 2 of them had a progression of their Cobb angle after the weaning point; the 2 other patients had a stabilization of their scoliosis. The Cobb angles of the progressive ones at the end of bracing were 42 and 51 degrees, respectively. Their Cobb angles at 2 years of follow-up after bracing visit were 48 and 61 degrees.

Regarding this particular subgroup of patients, surgery was required for only 1 patient, the one who had a Cobb magnitude of 51 degrees at the end of bracing and 61 degrees at the last visit after bracing. Surgical treatment was not an option for the other 3 patients.

5) Results stratified according to curve type, curve magnitude grouping, and skeletal maturity.

The results were analyzed separately according to curve type (thoracic, thoracolumbar, lumbar, and double curves), curve magnitude, and skeletal maturity (Tables 1 and 2). Bracing success depending on curve type (Table 1) was achieved at a rate of 56.8% for thoracic (37 + 5 = 42/74), 69.4% for thoracolumbar (29 + 5 = 34/49), 42.9% for double curves (13 + 2 = 15/35), and 83.3% for lumbar curve (8 + 2 = 10/12), comparing the initial Cobb angle with the one at maturity. To study the effect of curve magnitude on outcome, the patients were divided into 2 groups. Group 1 consisted of 67 patients whose curves magnitude at bracing was 25 to 29 degrees, and group 2 consisted of 103 patients with curve magnitude of 30 to 40 degrees. Group 1 had 70.1% of success compared with 52.4% of success for group 2. Comparison of brace success among initial Risser signs (Table 1) 0, 1, and 2 and at skeletal maturity is 46.4%, 88.9%, and 80.6%, respectively.

DISCUSSION

The purpose of this prospective observational study was to evaluate the effectiveness of the Dynamic SpineCor brace for adolescent idiopathic scoliosis after the standardized criteria proposed by the SRS Committee on Bracing and Nonoperative Management. In addition, we wanted to compare the effectiveness of the SpineCor brace with rigid braces, particularly the Boston brace,^{2,3} the Wilmington brace,⁴ the Milwaukee brace,⁵ the Charleston brace,^{6,15} and the Rosenberger brace.⁷ We used these reference articles as an alternative of other because they used very similar inclusion and exclusion criteria as in our study.

A previous study has been published in 2003 in *European Spine Journal*¹ on the first 195 patients from the same prospective cohort. This preliminary study in 2003 revealed that on the 29 patients who had a minimum

posttreatment follow-up of 2 years, 55% obtained a correction of their initial Cobb angle, 38% stabilized their Cobb angle, and only 7% worsened by more than 5-degree angle. The recent results follow a similar trend. Comparing the end of bracing Cobb angle to the one at 2 years after bracing, our study reveals that the follow-up of orthopaedic treatment was a success in 95.7% of the patients, with a mean correction angle of 8.6 ± 1.7 degrees. As reported by Montgomery et al,¹⁶ a follow-up of 2 years is sufficient to foresee progression after weaning from the brace. It seems possible with the SpineCor brace to have sustainable correction or stabilization of scoliotic curves up to 2 years after discontinuation of brace treatment.

Our results also demonstrated variable positive outcome for patients having a lumbar (83.3%), thoracolumbar (69.4%), thoracic (56.8%), and double curves (42.8%). Double curves were a little bit less successful compared with the other type of curves. This may be explained by the fact that we detected them later compared with the other types of curves because the posture is more often quite normal and they are more rigid. Positive outcome was also achieved for group 1 with 70.1% rate of success (initial curvature, between 25 and 29 degrees) compared with 50.2% for group 2 (initial curvature, between 30 and 40 degrees), comparing the beginning of bracing to the weaning point. Those results demonstrate the fact that it is possible to achieve higher rate of correction or stabilization when the conservative treatment is started in the early stage. Despite this fact, it was surprising to find out that success was attained in 46.4% of patients having an initial Risser sign of 0 compared with 88.9% and 80.6% for patients having a Risser sign of 1 and 2, respectively.

Although early reports indicated that the Milwaukee brace¹⁷ could afford some lasting reduction in the degree of spinal curvature, subsequent studies with longer follow-up demonstrated that after the cessation of brace treatment, curves that had demonstrated some correction at the end of bracing with traditional rigid braces tended then to continually increase toward the pretreatment angle.^{2,4,5,18} In the study of Noonan et al,⁵ 63% of the 88 patients wearing the Milwaukee brace were classified as a failure. Noonan et al showed that 27 patients (31%) had an arthrodesis; of these, 18 patients (67%) had curve progression while they wore the brace, and 9 (33%) had progression of the curve after a trial of intentional weaning. Similar loss of correction over time was also observed with other braces such as Wilmington and Boston braces. In the study of Gabos et al,⁴ 22% of 55 patients demonstrated an increase in the curvature of 5 degrees or greater between the end of bracing using the Wilmington brace and the time of final follow-up (mean, 14.6 years after the completion of treatment). In addition, 13% demonstrated an increase in the curvature of 5 degrees or greater between the end of bracing and the time of final follow-up that resulted in a curve that was 5 degrees or greater than the angle of deformity measured at the time of the initial treatment. Olafsson et al³ studied a population of patients with AIS wearing the Boston brace but with smaller curves (magnitude, 22 to 44 degrees). For this cohort of patients, the mean Cobb angle at treatment start was 32 ± 6 degrees, 12.1 ± 7.6 degrees

after bracing, 25.4 ± 11.3 degrees after weaning, and 29 ± 12 degrees at follow-up. However, our results show that it is possible to obtain a correction or a stabilization of the pretreatment Cobb angle (59.4%), and it seems possible to maintain the brace success for 2 years after the end of the treatment using SpineCor brace because only 2 of 47 patients who have completed the 2 years of follow-up had a curve worsening during this follow-up period.

In summary, the SpineCor Brace is effective for the treatment of AIS. Moreover, the positive outcomes are maintained up to 2 years of follow-up beyond skeletal maturity. This particular feature of the SpineCor brace makes it very different to the already published literature on brace, in which apparent correction obtained during treatment can be expected to be lost over time.^{4,18} However, future studies that will support and reinforce this finding are necessary. Forthcoming studies using the same standardized criteria for AIS brace studies as used in this study will allow valid and reliable comparison between the SpineCor brace and any other rigid braces.

REFERENCES

1. Coillard C, Leroux MA, Zabjek KF, et al. SpineCor—a non-rigid brace for the treatment of idiopathic scoliosis: post-treatment results. *Eur Spine J*. 2003;12:141–148.
2. Katz DE, Durrani AA. Factors that influence outcome in bracing large curves in patients with adolescent idiopathic scoliosis. *Spine*. 2001;26:2354–2361.
3. Olafsson Y, Saraste H, Soderlund V, et al. Boston brace in the treatment of idiopathic scoliosis. *J Pediatr Orthop*. 1995;15:524–527.
4. Gabos PG, Bojescul JA, Bowen JR, et al. Long-term follow-up of female patients with idiopathic scoliosis treated with the Wilmington orthosis. *J Bone Joint Surg Am*. 2004;86-A:1891–1899.
5. Noonan KJ, Weinstein SL, Jacobson WC, et al. Use of the Milwaukee brace for progressive idiopathic scoliosis. *J Bone Joint Surg Am*. 1996;78:557–567.
6. Trivedi JM, Thomson JD. Results of Charleston bracing in skeletally immature patients with idiopathic scoliosis. *J Pediatr Orthop*. 2001;21:277–280.
7. Spoonamore MJ, Dolan LA, Weinstein SL. Use of the Rosenberger brace in the treatment of progressive adolescent idiopathic scoliosis. *Spine*. 2004;29:1458–1464.
8. Lenssinck ML, Frijlink AC, Berger MY, et al. Effect of bracing and other conservative interventions in the treatment of idiopathic scoliosis in adolescents: a systematic review of clinical trials. *Phys Ther*. 2005;85:1329–1339.
9. Richards BS, Bernstein RM, D'Amato CR, et al. Standardization of criteria for adolescent idiopathic scoliosis brace studies: SRS Committee on Bracing and Nonoperative Management. *Spine*. 2005;30:2068–2075.
10. Goldberg CJ, Dowling FE, Hall JE, et al. A statistical comparison between natural history of idiopathic scoliosis and brace treatment in skeletally immature adolescent girls. *Spine*. 1993;18:902–908.
11. Goldberg CJ, Moore DP, Fogarty EE, et al. Adolescent idiopathic scoliosis: the effect of brace treatment on the incidence of surgery. *Spine*. 2001;26:42–47.
12. Roy M, Boutard A, Labelle H. La radiologie numérique permet-elle vraiment de diminuer l'exposition aux radiations chez les adolescents avec scoliose idiopathique? Conference Proceedings of the annual Meeting of the Communication Société de la scoliose de Québec. 1997.
13. Bitan FD, Veliskakis KP, Campbell BC. Differences in the Risser grading systems in the United States and France. *Clin Orthop Relat Res*. 2005;190–195.
14. Ponseti IV, Friedman B. Prognosis in idiopathic scoliosis. *J Bone Joint Surg Am*. 1950;32A(2):381–395.
15. Gepstein R, Leitner Y, Zohar E, et al. Effectiveness of the Charleston bending brace in the treatment of single-curve idiopathic scoliosis. *J Pediatr Orthop*. 2002;22:84–87.
16. Montgomery F, Willner S, Appलगren G. Long-term follow-up of patients with adolescent idiopathic scoliosis treated conservatively: an analysis of the clinical value of progression. *J Pediatr Orthop*. 1990;10:48–52.
17. Edmonsson AS, Morris JT. Follow-up study of Milwaukee brace treatment in patients with idiopathic scoliosis. *Clin Orthop Relat Res*. 1977;58–61.
18. Bassett GS, Bunnell WP, MacEwen GD. Treatment of idiopathic scoliosis with the Wilmington brace. Results in patients with a twenty to thirty-nine-degree curve. *J Bone Joint Surg Am*. 1986;68:602–605.